

The aid of Neural Therapy in the resolution of partial rupture of the anterior and posterior cruciate ligaments in a male patient: A case report



Bruna Aparecida Lima Gonçalves^{a*}  | Leonardo Rocha Vianna^b 

^aPontifícia Universidade Católica de Minas Gerais, MG, Brazil.

^bUniversidade Federal de Minas Gerais, MG, Brazil.

*Corresponding author: bruna_alg@yahoo.com.br

Abstract The knee injury is the most common among the serious injuries presented by soccer players, highlighting the anterior cruciate ligament as one of the most frequently injured knee ligaments. Posterior cruciate ligament injuries are uncommon and are usually associated with other concomitants, such as meniscus disease. Neural Therapy is defined as using local anesthetics in low concentrations according to the patient's life history, with the objective of body self-regulation. Procaine hydrochloride has cell repolarization functions and analgesic, antimicrobial, anti-inflammatory, and healing effects. This study aims to report the case of a conservative treatment performed on a 33-year-old male patient with partial rupture of the anterior and posterior cruciate ligaments after a fall in a football match and his recovery after treatment with a return to physical activity.

Keywords: local anesthetics, self-healing, ligament consolidation, cell repolarization

1. Introduction

The knee is one of the joints most susceptible to ligament injuries. It is located in the middle of the leg between the femur and the tibia, suffering a greater number of rotational forces. The cruciate ligaments intertwine and are the primary rotational stabilizers of the knee (Silva et al 2010). The knee is considered the most complex joint in the human body and plays the most important role in locomotion (Brito et al 2008).

As for the ligaments, they connect the bones and are responsible for the stability of the knee. There are four ligaments that connect the femur to the tibia: two collaterals that stabilize the knee lateromedially (medial and lateral collateral ligaments) and two intra-articular (the anterior and posterior cruciate ligaments) that control the movement of the knee anteroposteriorly (Pinheiro and Sousa 2015).

The posterior cruciate ligament (PCL) is the main structure responsible for preventing the posterior translation of the knee, having an anterolateral bundle and a posteromedial bundle (Costa and Rodrigues 2016). PCL injuries are uncommon, but the risk is higher in soccer players (Costa and Rodrigues 2016). Soccer players perform various sporting gestures: running, jumping, passing, shooting, dribbling, braking, and starting that subject the player to a set of macro traumas and functional overload injuries, making the knee a particularly vulnerable joint, so these athletes have a high incidence of knee tendinopathies (Brito et al 2008). The posterior cruciate ligament (PCL) is the most stable ligament in the knee, so its injuries occur as a consequence of high impacts (Toqueton et al 2022). The posterior cruciate ligament is the strongest in the knee, exerting twice as much tension as the anterior cruciate ligament, so therapeutic management of PCL injuries is crucial (Toqueton et al 2022).

The PCL often heals with continuous tissue development due to its regenerative potential with increased vascularization, which can act as a limiter of the posterior tibial drawer and, in this way, partially explain the favorable prognosis of these injuries (Costa and Rodrigues 2016). The treatment of PCL injuries is controversial, as this injury is usually associated with injury to the anterior cruciate ligament or menisci indicated for surgical treatment (Costa and Rodrigues 2016). Concurrent anterior cruciate ligament (ACL) injuries with lateral meniscus root tears are the most common type of concomitant injury (Toqueton et al 2022). PCL tears may or may not be associated with meniscus tears (Toqueton et al 2022). If both the anterior cruciate ligament (ACL) and the posterior cruciate ligament (PCL) are injured, it is recommended that you follow the PCL protocol (Silva et al 2010).

Restoration of the posterior cruciate ligament is a more careful intervention when compared to a reconstruction of the anterior cruciate ligament. Knee reconstruction is complex and requires understanding (Toqueton et al 2022). The main



posterior cruciate ligament restoration techniques are open ligament repair, traditional reconstruction, and arthroscopic reconstruction (Silva et al 2010; Toqueton et al 2022). According to Costa and Rodrigues (2016), half of the patients can resume the same level of sports activity, and a third can resume the same sport but at a lower level.

Treatment of an ACL injury depends on the type of injury, such as a torn ligament, a partial ligament tear, or a complete ligament tear. The patient and the doctor can opt for surgical or conservative treatment, depending on factors such as age, the extent of associated injuries, the possibility of rehabilitation, and the patient's lifestyle (Pinheiro and Sousa 2015). In general, conservative treatment is used in partial ruptures, and in total breaks, the surgical or conservative method is chosen (Pinheiro and Sousa 2015).

Surgical techniques for ACL reconstruction include single-bundle anterior cruciate ligament reconstruction so that only one graft is used to replace both bundles of the ACL. There is also the double-bundle reconstruction technique, in which different grafts are used to replace each ACL bundle. Ligament restoration of the anterior cruciate is usually achieved when the reconstruction allows stabilization of the knee that allows the patient to return to physical activity and to perform daily activities prior to the partial or total tear of the ACL. Some literary studies have concluded that the rupture of the anterior cruciate ligament does not allow the standard structural and functional restoration of the knee, and therefore only 60% of the patients returned to the practice of sport, also due to osteoarthritis changes and emotional insecurity (Brito et al 2008; Toqueton et al 2022).

Radiography, axial computed tomography (ACT) and Magnetic Resonance (MR) are complementary diagnostic tests. ACT is used when it is impossible to perform MR, as MR allows better visualization of the ligaments, cartilage, and other knee components (Pinheiro and Sousa 2015).

Treatment with Neural Therapy is done through applications of a local anesthetic, such as procaine, with unique dielectric properties, which produces local and segmental responses in the body (Molano et al 2014). It aims at body self-regulation, restores tissue physiological conditions, and can be used in chronic pain, arthropathies, chondropathies, and connective tissue disorders (Mermod et al 2008; Fleckenstein et al 2018). According to Michels et al (2018) local anesthetics are effective in reducing and controlling pain and remission of chronic and neuropathic pain.

In 1860 Albert Niemann discovered cocaine which was the first local anesthetic. In 1884, Carl Koller used it in clinical practice in ophthalmological surgeries. But due to its toxicity, procaine was synthesized and could have clinical use (Carvalho 1994). Procaine is the first injectable synthetic local anesthetic discovered in 1905 by Alfred Einhorn (Akcal et al 2015). It is hydrolyzed to diethylaminoethanol alcohol (DEAE) and para-aminobenzoic acid (PABA). In 1906 its anti-inflammatory effect was reported by Vychnevski (Brobyn et al 2015). In 1906 Spiess observed the healing effect of procaine on inflammatory processes, where wounds healed faster and with a lower degree of complications (Gonçalves et al 2020). Healing action is also mentioned by Klinghardt (2002).

Procaine has a compelling therapeutic potential (Muri et al 2010). Local anesthetics have neuroprotective, antithrombotic, and immunomodulatory effects (Vinyes et al 2022), antimicrobial action (bacteria, fungi, and viruses), and anti-inflammatory and analgesic effects (Cassuto et al 2006).

Local anesthetics, such as lidocaine and procaine, can be used in concentrations from 0.1 to 1%, in regions according to the life history of each patient. At these concentrations, they function as dielectric substances, allowing the cell reestablishment of affected cells, and normalizing the membrane potential of diseased cells (Cruz and Fayad 2011). The German medical brothers Ferdinand and Walter Huneke delved into the practice of using local anesthetics and found that procaine had an analgesic effect and acted immediately on patients (Faber 1989).

According to Vianna and Gonçalves (2021), 0.7% procaine hydrochloride is a dielectric substance that has up to 207 mV and allows cellular repolarization of diseased cells and later return of cell membrane potential. Application sites can be painful points, trigger points, scars, nerve emergency zones, acupuncture points, intra-articular, intraperitoneal, intravenous, ganglionic, and head zones, among others (Weinschenk 2012; Gonçalves et al 2020).

This paper aimed to report the case of conservative treatment in a 33-year-old male patient with partial rupture of the anterior and posterior cruciate ligaments with Neural Therapy.

2. Case report

Physically active male patient who practices futsal and field soccer twice a week, 33 years old, weighing 100 kg and 1.89 cm in height. During a futsal game on May 17, 2016, in an aerial ball dispute, the opposing player made a movement with his head and hit him on the head, causing fainting and a consequent sudden fall. The next day, he had a massive joint effusion, limited range of motion in the flexion movement of the left knee, and pain. He was without physical activity for 24 days, and even so, the pain remained, even using meloxicam 15 mg for ten days from the Medley laboratory.

On June 11, when returning to sports, he had a sprain with pain and swelling during a field soccer match. On June 14, he was evaluated by an orthopedist who suspected injury to the anterior cruciate ligament and posterior cruciate ligament due to swelling and pain at the site, indicated ten physiotherapy sessions, and referred for an MR to confirm the diagnosis.

On July 28, the patient underwent an MR that revealed a partial rupture of the left knee's anterior and posterior cruciate ligaments (Board 1).

Board 1 MR report. Day 07/28/2016.

<p>Observed aspects:</p> <p>High-grade partial lesion of the posterior cruciate ligament characterized by thickening and heterogeneity of its fibers, with discontinuity of most of the central and anterior ligament fibers.</p> <p>Partial anterior cruciate ligament injury characterized by diffuse thinning and fiber heterogeneity.</p> <p>The sufficiency of the remaining fibers of such ligaments must be correlated with clinical examination data.</p> <p>Trochlear chondropathy is characterized by deep fissures of the chondral lining of the femoral trochlea sulcus associated with foci of subchondral medullary edema.</p> <p>Small Baker's cyst.</p> <p>Discrete joint effusion.</p>

Until then, the medical recommendation was for surgical treatment, with the reconstitution of the ligaments in 2 surgeries. However, as the recovery time and return to activities was 18 months, a conservative (non-surgical) attempt was chosen, even with a low probability of success, according to the orthopedic doctor.

Following the conservative path, on August 17, he has referred again, after a new evaluation with the orthopedist, for 20 physiotherapy sessions, but the patient still felt pain and joint instability, even with physiotherapy. With that, it was decided to start Neural Therapy. The physical therapy treatment lasted approximately 1 hour per session and specific exercises to strengthen the knee and muscles.

Parallel to the physiotherapy sessions, the treatment was started with the technique of Neural Therapy, aiming at body stimulation to potentiate ligament regeneration. The sessions were weekly, totaling four sessions, with 0.7% procaine hydrochloride being applied, with a 4.5 x 13 mm insulin needle, in the acupoints “eyes of the knee” (Figure 1) and VB 34 (Figure 2), which is the point of ligaments and tendons. The patient noted improvement in pain and stability.

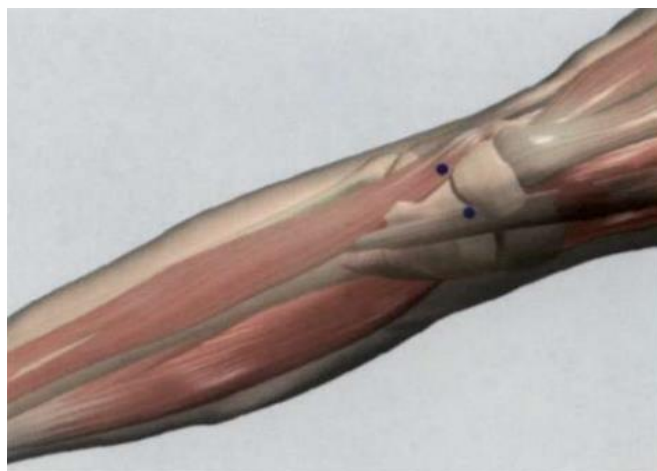


Figure 1 Region of the “eyes of the knee” acupoints (Lian et al 2012).

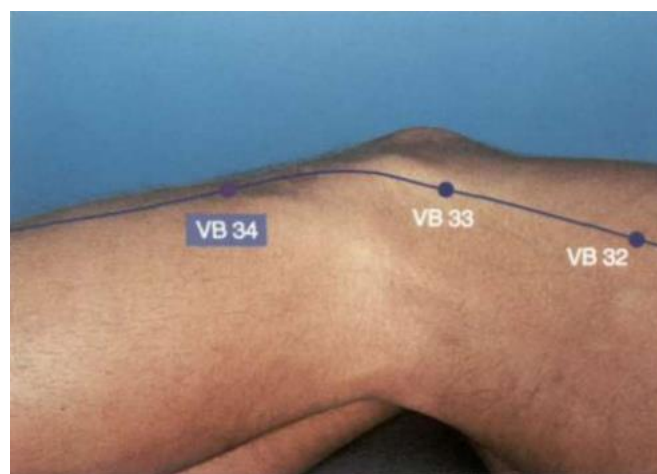


Figure 2 Acupoint VB 34 highlighted (Lian et al 2012).

On September 26, the patient was re-evaluated by the orthopedist, who observed improvement in the tests and referred him to the gym for muscle strengthening - quadriceps, flexors, adductors, abductors, glutes and calves, and proprioception. On December 7, 2016, the patient underwent another MRI that revealed signs of resolution of the ligament injury (Board 2). The patient returned to playing football in January 2017 and continues to this day together with tennis.

Board 2 MR report, 12/07/2016.

<p>Observed aspects:</p> <p>Partial intra-substantial rupture in the phase of resolution/resorption of the posterior cruciate ligament, without evidence of secondary bone avulsion, the ligament edematous, maintaining continuity, with no ligament "gap".</p> <p>Absence of established/remaining anterior cruciate ligament injuries, the same with normal orientation, thickness and signal characteristics in all pulse sequences and planes obtained.</p> <p>Full-thickness chondral lesion through the middle and distal thirds of the femoral trochlea throat, touching the adjacent subchondral bone by longitudinal extension. Collateral ligaments and other structures of the posterolateral corner do not show abnormalities.</p> <p>Small accumulation of fluid in the semimembranous gastrocnemius bursa.</p>

3. Discussion

As mentioned in the report and corroborated by Brito et al (2008), the risk of injury in soccer is high. Knee injury is the most common injury among serious injuries that occur in soccer players. The anterior cruciate ligament (ACL) is one of the most frequently injured knee ligaments. According to Silva et al (2010), knee ligament injuries are among the main injuries that occur in sports. Combined injuries of the cruciate ligaments are rare, and these injuries are usually associated with high-impact trauma. However, in this case, both anterior and posterior cruciate ligaments were injured. According to these authors, surgical intervention is necessary in these cases due to the high level of instability. According to Arliani et al (2012), the ACL ligament does not heal properly after the injury. Currently, surgical reconstruction is the standard treatment for athletes. According to Brito et al (2008), the treatment usually involves surgical reconstruction of the injured ACL, associated with a prolonged rehabilitation period. However, in the case reported, the conservative treatment was effective for repairing the cruciate ligaments, and surgery was unnecessary. Pinheiro and Sousa (2015) mention that the treatment of ACL injury depends on the type of injury. It is a decision between the doctor and the patient, evaluating the various factors such as the degree of injury, availability for rehabilitation, and age of the patient, among others.

There is some controversy in treating PCL injuries because this injury is usually associated with injury to the anterior cruciate ligament or menisci indicated for surgical treatment (Brito and Rodrigues 2016). According to Pinheiro and Sousa (2015) the treatment of ACL injury depends on the type of injury. In general, conservative treatment is used in partial ruptures, and in complete ruptures, the surgical or conservative method is chosen, depending on the patient's characteristics. Both treatments are effective and have good results depending on the type of injury.

Conservative treatment aims at analgesia and stabilization of knee dynamics through muscle strengthening and proprioceptive training (Pinheiro and Sousa 2015). Conservative treatment is indicated in the following situations: partial rupture and no symptoms of instability; complete rupture and no symptoms of instability during physical activity; individuals who have sedentary lifestyles or who perform light manual work; and in children because they have open growth plates (Pinheiro and Sousa 2015).

Like all surgeries, ligamentoplasty has associated risks, such as: infection, stiffness, knee instability, and recurrence of the lesion and bleeding. Open ligament reconstruction surgery is only performed if complications arise during the arthroscopic surgery (Pinheiro and Sousa 2015).

Procaine hydrochloride has analgesic, anti-inflammatory, antimicrobial, and cellular repolarizing actions (Cassuto 2006; Muri et al 2010). Even with physical therapy, the patient felt pain and joint instability, but after starting Neural Therapy, he reported improvement in pain and instability. Neural Therapy can be used in dermatological, inflammatory, infectious, pain, musculoskeletal conditions, and plantar fasciitis, among other diseases (Mermod et al 2008; Bulcão et al 2011; Fleckenstein et al 2018; Vianna and Gonçalves 2021).

Neural Therapy is a treatment that can be used in acute and chronic diseases. A study in patients with nonspecific LBP demonstrated the effectiveness of Neural Therapy on acupuncture points (Medrano Garcia et al 2011). According to Molano et al (2014), Chinese medicine has described energy channels for many years; 235 acupoints correlate with head zones. According to Head in 1898, some visceral diseases are reflected in sensitive skin regions. As shown by Gonçalves et al (2020), the VB 34 acupoint was also used in a case of common Achilles tendon rupture, in addition to other acupoints and local treatment.

Neural Therapy and acupuncture are known as regulatory medicines because they activate the body's compensatory-regulatory mechanisms to generate responses against disease and restore balance (Weinschenk 2012; Bayona 2018).

4. Final considerations

Neural Therapy is a growing treatment in Brazil that has been disseminated and increasingly showing positive results. Because it is minimally invasive, it becomes a safe technique in addition to being self-regulating and seeks to rebalance the body. Currently, the association of procedures and treatments is growing with the ultimate goal of benefiting patients. It was possible to demonstrate the benefit of Neural Therapy as a form of treatment in resolving ruptures of the anterior and posterior cruciate ligaments

Conflict of Interest

The authors declare that there is no conflict of interest.

Funding

There was no funding for this work.

References

- Bayona YPV (2018) Efecto de la acupuntura y de la terapia neural, sobre un organismo biologico como el hombre. Una posibilidad terapeutica como medicina integrativa. Dissertação, Universidade Nacional da Colombia, Bogotá.
- Bulcão RP, Arbo MD, Roehrs M, Paniz C, Cervi FL, Thiesen, FV, Leal MB; Garcia SC (2011) Procaína: Efeitos farmacológicos e toxicológicos. *Revista de Ciências Farmacêuticas Básica e Aplicada* 32:297-303.
- Brito J, Soares J, Rebelo AN (2009) Prevenção de lesões do ligamento cruzado anterior em futebolistas. *Rev Bras Med Esporte* 15:62-69.
- Brobyn TL, Chung MK, Lariccia PJ (2015) Neural Therapy: An Overlooked Game Changer for Patients Suffering Chronic Pain?. *J. Pain. Relief.* 4.
- Cassuto J, Sinclair R, Bonderovic M (2006) Anti-inflammatory properties of local anesthetics and their present and potential clinical implications. *Acta Anaesthesiologica Scandinavica* 50:265-282.
- Carvalho JCA (1994) Farmacologia dos anestésicos locais. *Revista Brasileira de Anestesiologia* 44:75-82.
- Costa RNV, Rodrigues E (2016) Tratamento Conservador de uma rotura parcial do ligamento cruzado posterior no Futebol – Estudo de Caso. Dissertação, Escola Superior de Tecnologia da Saúde.
- Cruz Y, Fayad R (2011) Microtúbulos y terapia neural: propuesta de una investigación promisoría. *Revista Med de la Facultad de Medicina* 19:82-92.
- Faber WJ (1989) A Review of Neural Therapy – Rapid Therapeutic Response for Nerve and Fascial Lesions. *Journal of Orthomolecular Medicine* 4:174-177.
- Fleckenstein J, König M, Banzer W (2018) Neural therapy of an athlete's chronic plantar fasciitis: a case report and review of the literature. *Journal of Medical Case Reports* 12:233.
- Gonçalves BAL, Vianna, LR, Mendes ACR, Rocha APC; Muniz DD (2020) Terapia Neural no tratamento de ruptura de tendão calcâneo comum: Relato de caso. *PUBVET* 14:1-7.
- Klinghardt DK (2002) Neural therapy. *Explore* 11:01-05.
- Medrano Garcia R, Varela Hernández CA, De La Torre Rosés M, Mendoza Cisneros R, Acosta Davison Y (2011). Resultados de la aplicación de la terapia neural en la lumbalgia inespecífica. *Revista Arch. Méd. Camagüey* 15.
- Mermod J, Fischer L, Staub L, Busato A (2008) Patient satisfaction of primary care for musculoskeletal diseases: A comparison between Neural Therapy and conventional medicine. *BMC Complementary and Alternative Medicine* 8:33.
- Michels T, Ahmadi S, Graf N (2018) Treatment of peripheral pain with low-dose local anesthetics by epidermal, epithelial and periosteal application. *Local and Regional Anesthesia* 11:129-136.
- Molano MLB, Bonilla LBP, Dussan EHB, Londoño CAV (2014) Anatomic-functional correlation between head zones and acupuncture channels and points: a comparative analysis from the perspective of neural therapy. *Evidence-Based Complementary and Alternative Medicine* 1-12. DOI: 10.1155/2014/836392.
- Muri EMF, Sposito MMM, Metsavaht L (2010) Efeitos secundários potencialmente desejáveis dos anestésicos locais. *Acta Fisiatr* 17:28-33.
- Silva KNG, Imoto AM, Cohen M, Peccin MS (2010) Reabilitação Pós-operatória dos Ligamentos Cruzado Anterior e Posterior – Estudo de Caso. *Acta Ortop Bras* 18:166-9.
- Toqueton TR, Melo LB, Lindemann C M, Fernandes JGF, Júnior JAF, Dias HFR, Pavoni BC, Araújo MS, Costa RH, Silva, SCM, Oliveira MPA, Meireles AM, Veloso VBM (2022) Técnicas cirúrgicas reparadoras de lesões do ligamento cruzado posterior: uma revisão. *Brazilian Journal of Development* 8:43396-43406.
- Vianna LR, Gonçalves BAL (2021) pH e condutividade do cloridrato de procaína em diferentes concentrações utilizadas na terapia neural. *Multidisciplinary Science Journal* 3:e2021002:1-5.
- Vinyes D, Munõz-Sellart M, Caballero T G (2022) Local anesthetics as a therapeutic tool for post COVID-19 patients A case report. *Clinical Case Report Medicine* 101:1-6.
- Weinschenk S (2012) Neural therapy-A review of the therapeutic use of local anesthetics. *Acupuncture and Related Therapies* 4:5-9.

