

Infrared thermography as a method of diagnosing reproductive pathologies in animals



Pavlo Skliarov^a   | Serhiy Fedorenko^b  | Svitlana Naumenko^b  | Oleksandr Onyshchenko^b  |
Dmytro Bilyi^a  | Roman Mylostyvyi^a  | Viacheslav Vakulyk^a  | Liliia Kuraksina^b 

^aDnipro State Agrarian and Economic University, Serhii Yefremov Str., 25, Dnipro, 49600, Ukraine.

^bState Biotechnological University, Alchevskykh Street, 44, Kharkiv, 61002, Ukraine.

Abstract The development and practical implementation of unique instrumental methods for diagnosing obstetric, gynecological, and andrological pathologies remain relevant. In this regard, thermography shows promise as a non-contact remote diagnostic express method that allows detecting differences in the distribution and intensity of infrared radiation depending on the physiological or pathological state of the animal organism. In this regard, the purpose of the work was to present the possibility of using the infrared thermography method for diagnosing reproductive pathologies in animals. Assessing the functional state and conducting preventive diagnosis of pathological processes in the genitals using thermal imagers can be crucial in animal reproduction. In addition, exceptional safety, autonomy, and non-contact qualities make thermal imagers indispensable in veterinary medicine. Therefore, thermography provides identification and differentiation of the phases of the sexual cycle and preventive diagnosis of obstetric-gynecological and andrological pathologies at a pre- or subclinical stage of development, dystrophic or inflammatory. Practical utilization of thermal imagers enables, in some cases, to make a final diagnostic conclusion; in others, to receive only preventive information followed by thorough, further comprehensive and specific research.

Keywords: non-invasive method, reproductive organs, thermal imaging diagnostics

1. Introduction

An unsolved problem in the diagnosis of many reproductive pathologies in animals is the detection of pre- or subclinical manifestations and confirmation of clinical symptoms obtained by objective examination methods (Roberto and De Souza 2020; Mota-Rojas et al 2022; Skliarov et al 2022). Therefore, developing and practically implementing unique instrumental procedures for diagnosing obstetric, gynecological, and andrological pathologies remains relevant (Stelletta et al 2013; Koshevoj 2015; Skliarov et al 2019).

Thermal imaging diagnostics can be promising in this regard, which allows for characterizing specific features of the structure (morphology) or function of the organ under study (Stelletta et al 2013; Rekant et al 2016; Pasternak et al 2017). Thermography is a promising non-contact remote diagnostic express method. Being a wholly harmless and objective method of examination, it allows the detection of differences in the distribution and intensity of infrared radiation depending on the physiological or pathological state of the animal body (Kunc and Knizkova 2012; McManus et al 2016; Jeyakumar et al 2022).

Considering the above, the purpose of the work was to present the possibility of using the infrared thermography method for diagnosing reproductive pathologies in animals.

2. Biophysical aspects of thermal vision

Thermal imaging is a method of recording infrared radiation of anybody whose temperature is above absolute zero. This radiation is captured and recorded by special susceptible devices – thermal imagers (Gade and Moeslund 2014; Tattersall 2016; Nääs et al 2020).

In the animal body, a large amount of heat is produced due to exothermic biochemical processes in cells and tissues and the release of energy associated with the synthesis of DNA and RNA. This heat is distributed within the body with the help of circulating blood and lymph. Blood circulation equalizes temperature gradients. Due to its high thermal conductivity, blood does not change due to the nature of the movement. It can carry out intensive heat exchange between the central and peripheral regions of the body. Mixed venous blood is the warmest. It cools a little in the lungs and, spreading over a large circle of blood circulation, maintains the optimal temperature of tissues, organs, and systems. The temperature of the blood passing through the skin vessels drops by several degrees Celsius. In pathology, the circulatory system is disturbed. Changes occur because increased metabolism, for example, in the focus of inflammation, increases blood perfusion and, therefore, thermal conductivity, which is reflected on the thermogram by the appearance of a focus on hyperthermia (Knizkova et al 2007; McManus et al 2016; Mota-Rojas et al 2022).



Warmth, so the temperature of the animal's skin, has its particular topography and is an integral indicator formed by several factors: the vascular system (regulates the temperature due to changes in the diameter of peripheral arteries, veins, capillaries); level of exchange processes and thermal conductivity and heat transfer. When reading thermograms, it is necessary to take into account all these factors; however, the main one is vascular, which determines the main thermal imaging symptoms in clinical veterinary medicine (Kunc and Knizkova 2012; Stelletta et al 2013; Casas-Alvarado et al 2020).

3. The technique of using a thermal imager

For the reliability of the results, the following factors must be considered: movement, artifacts, ambient temperature, and energy from external heat sources. The physician should immobilize the animal, avoiding a long examination period, although thermography reduces the need for complete immobilization. Sedatives and tranquilizers should be excluded because these drugs affect the peripheral circulation and cardiovascular system and can lead to false thermal images. Thermography should be performed under a shelter protected from sunlight to reduce the effect of energy from external heat sources. It is best to perform thermography in low light. The ambient temperature should be between 10-20 °C, but any constant temperature is acceptable. The place where thermography is performed must have a constant flow of air so that there is no false decrease in temperature. For practical reasons, the animal should be kept away from drafts.

During thermographic studies in veterinary medicine, the scanning speed is essential since achieving the long-term immobility of an animal without general anesthesia is challenging. The scanning speed of up to 8 frames per second is sufficient. The thermal imager's memory card allows registering up to 6000 thermograms with a size of 120×160 pixels (for example, TI-120; manufacturer: Zhejiang ULIRVISION Technology Co, Ltd).

The minimum size of the object whose temperature can be measured depends on the distance between the thermal imager and the object. The highest resolution (the minimum distance between adjacent points of the object under investigation, which on the thermogram correspond to two adjacent pixels) is achieved when the device is placed 30 cm from the object under investigation and is 0.5 mm. However, reliable results can be obtained at a longer distance of 1-2 m or more.

Color palette. The value of the temperature gradient can be assigned a different color, which is presented in the software of the thermal imager.

A notation system has been developed to determine thermograms from the body surface that simplifies their description and statistical processing of experimental results.

Solving diagnostic tasks is facilitated by a standard of the so-called normal thermogram. Identifying the difference between the norm and pathology depends on the qualifications of the thermologist. It is necessary to know the approximate values of temperature differences to detect pathology.

For a more accurate study of the object under study, thermographic images can be transferred to a personal computer, where with the help of a particular program (a set of statistical data of thermogram processing functions), it will be possible to unify them. Also, for each thermographic image, one can get a corresponding report, which will certify the conditions under which the research was carried out (temperature, humidity, distance to the object under study), temperature analysis of the image (maximum, minimum, and average values), as well as thermal and histogram (Sykes et al 2012; Koshevoj 2013; McManus et al 2016).

4. The use of thermography in veterinary reproductive medicine

4.1. Preventive remote project diagnostics of sexual cycle phases in animals

Hurnik et al (1985) studied the relationship between body surface temperature difference and estrus in Holstein-Friesian dairy cows and the possibility of using this technique to determine the onset of estrus. Since inaccuracies in determining the estrous cycle were found during the experiment, the authors did not recommend thermography for the usual estrus detection. Still, it is adequate for studies of skin temperature or, more precisely, for changes in body surface temperature.

The studies conducted by Stelletta et al (2013) reported dedicated thermographic monitoring sessions to optimize hormonal treatment during ovarian synchronization protocols in the mare and ewe. In general, the skin temperature of the vulva and pre-vulvar areas can help increase awareness of the time of ovulation. In these areas, thermal radiation is associated with skin or subcutaneous blood flow changes. During estrus, the increase in blood flow usually depends on the level of estrogen secretion by the growing ovarian follicles (Stelletta et al 2013).

Preventive diagnostics of the phases of the sexual cycle using thermal imaging can be used for females of various animal species (Stelletta et al 2013). The obtained information is confirmed by other research methods with mandatory elements of differentiation (Koshevoj 2013).

4.1.1. Cows and adult heifers

Low oestrus detection rates (>50%) are associated with longer calving intervals, lower economic returns, and reduced longevity in Holstein dairy cows. According to Marquez et al (2021), a combination of thermal and behavioral parameters

increased the accuracy of estrus detection compared to temperature or behavioral biometric data, regardless of the cows' natural cycle during milking.

Based on their research, Vicentini et al (2020) believe that infrared thermography is an effective method for detecting temperature fluctuations during proestrus and the estrus phase in heifers.

It is known that the optimal time for the insemination of cows is the heat, which varies significantly from 8-12 hours. In winter and up to 24-36 hours. Summer season. This situation creates problems for the practice of artificial insemination. Moreover, the clinical severity of the phenomena of the sexual cycle in cows is different, which depends on their completeness. Considering this, a method of preventive diagnostics using thermal imaging devices has been developed. Therefore, the thermogram of the external genital organs of cows in estrus is characterized by the predominance of more "hot" colors of the palette (red) and in the phase of diestrus – warm (orange) (Figure 1). At the same time, the temperature of the external genitalia decreases by $1.3\text{ }^{\circ}\text{C}$ (3.8%) – $34.5\pm 0.3\text{ }^{\circ}\text{C}$ to $33.2\pm 0.5\text{ }^{\circ}\text{C}$ (Koshevoj 2013).

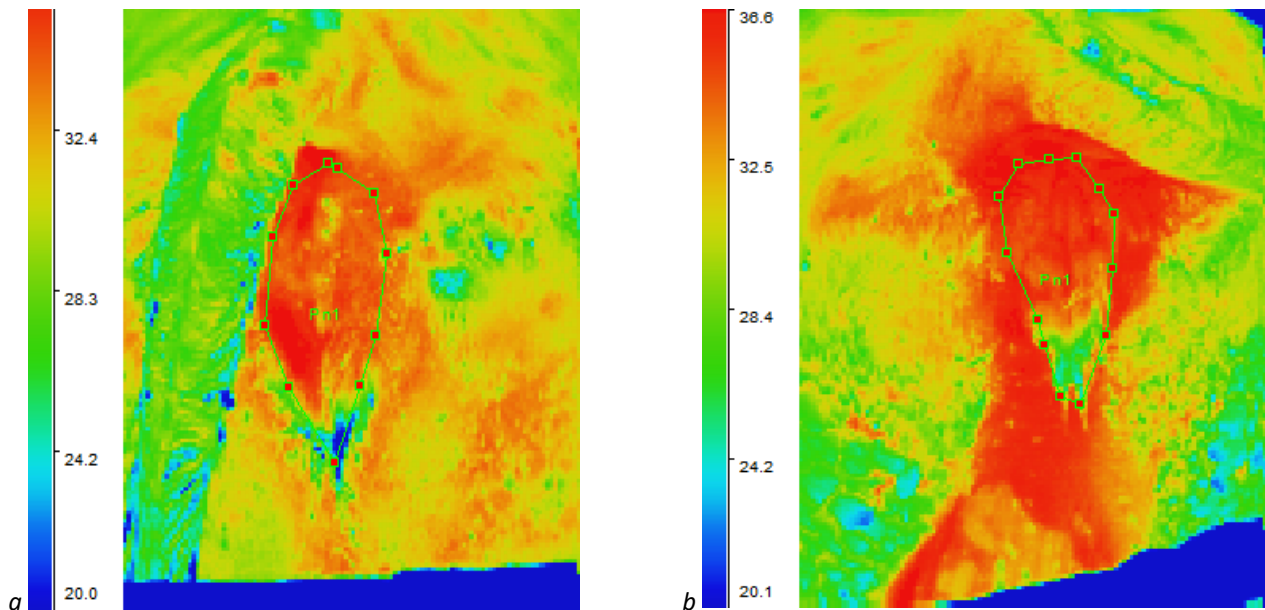


Figure 1 Thermogram of the external genital organs of cows: a) the balancing stage (diestrus, 12-15 days of the cycle); b) the arousal stage of the sexual cycle (estrus 3-5 days). *Source:* Koshevoj (2013).

4.1.2. Sheep and goats

Detection of oestrus in goats usually involves invasive methods that are less accurate because they are subjective, require significant time and resources, and may cause animal welfare problems. Infrared thermography is one of the alternative solutions because this method is modern, non-invasive, and safe (Pamungkas et al 2022).

De Freitas et al (2018) note the effectiveness of thermography in detecting small temperature fluctuations during different phases of the estrous cycle, allowing the identification of different stages of the cycle in Santa Ines sheep.

The thermoscopic and thermographic methods when conducting preventive remote project diagnostics of the phases of the sexual cycle in small female cattle are similar to that described for cows and heifers. Research considers the peculiarities of the reproduction of sheep and goats, that is, the seasonality of the manifestation of sexual function.

Depending on the phenomena, the temperature fluctuations of the external genital organs are recorded thermoscopically - in the estrus phase, they are characterized by large areas of "hot" colors of the palette, and their temperature in goats is $33.2\pm 0.2^{\circ}\text{C}$, which is 1.7°C (5.1%) is higher than in animals with diestrus – $31.5\pm 0.4^{\circ}\text{C}$. In sheep, this indicator was higher by 1.2°C (3.4%) and was $35.5\pm 0.2^{\circ}\text{C}$ and $34.3\pm 0.3^{\circ}\text{C}$, respectively (Koshevoj 2013; Skliarov et al 2014; Skliarov et al 2022).

4.1.3. Mares

Diagnosis of estrus in mares is based on two main methods: the clinical-visual method – observation of the behavior of mares, the manifestation of characteristic signs from the external genital organs (yawning and "flickering" of the vulva), and the reflexological method - the use of a test male. These methods have certain disadvantages - the clinical-visual method is entirely subjective and requires much time to observe the animal, the reflexological method is quite traumatic for both the mare and the stallion, requires reliable fixation, the construction of unique fences and can lead to unwanted mating individuals. All this indicates the need to develop new methods, including preventive (preliminary) remote trauma-safe and objective diagnosis of the phases of the sexual cycle in mares (Stachurska et al 2023).

The developed method of remote thermal imaging diagnosis of estrus in mares consists of the study of her external genitalia, fixation, and analysis of thermograms, followed by differentiation of the presence or absence of signs of estrus.

During the study, attention is paid to the temperature difference between the mare's vulva and the surrounding tissues. With an adverse diagnostic reaction (diestrus), the temperature difference between the vulva and the surrounding tissues is almost not noticeable (no more than 1 °C), or even the vulva is somewhat cooler than the perineal areas – the low concentration of estrogens in the blood causes a trim level of blood supply to the genitals. The area of the external genitalia and perineum is warmer than the croup, but not significantly – within 0.4-0.9 °C.

With a positive diagnostic reaction, the area of the external genitalia shows more significant temperature fluctuations. This area is 3-4°C hotter than the surrounding tissues of the croup, which is explained by pronounced hyperestrogenemia and active hyperemia during the estrus phase of the sexual cycle and can serve as a signal for further more detailed examination of the animal (rectal determination of the degree of follicle maturity, etc.) (Koshevoj 2013).

4.1.4. Pigs

Determining the optimal time of insemination in pigs significantly impacts the herd's fertility and the offspring's size. Still, it was and remains an actual and somewhat problematic issue (Simões et al 2014). Today, the main methods of diagnosing estrus are reflexological (with the help of a test boar) and clinical-visual (by detecting the hugging reflex in sows). This work is traumatic and requires much physical effort and contact with animals. It is necessary to predict the condition of the genitals to reduce the number of "tests" and increase the probability of the result. This becomes possible when using information and diagnostic devices, particularly thermal imagers.

The developed method of preventive remote diagnosis of the phases of the sexual cycle in pigs using thermal imaging technology is based on the determination of changes in the temperature gradients of the external genital organs in sows showing signs of estrus. An increase in the temperature of the external genitalia occurs due to an increase in the concentration of estrogens in the blood of animals, which is accompanied by active hyperemia.

The technique consists of remote non-contact research of females both in group and individual housing. The thermal imager measures the temperature gradient of the external genitalia, surrounding tissues, and the external environment (room).

During an adverse reaction (diestrus), the temperature of the external genitalia is almost no different from that of the surrounding tissues (no more than 1 °C, while the perineum can be even warmer than the temperature of the vulva). Instead, a positive reaction (estrus) is characterized by a temperature difference of 2-3 °C.

Per preventive thermal imaging diagnostics results, pigs with a positive diagnostic reaction are separated from the herd and examined by clinical-visual or reflexological methods to clarify the fertile period (Koshevoj 2013).

4.1.5. Rabbits

Sexual activity in rabbits is not characterized by rhythmicity. During sexual arousal, against the background of long-term proliferative processes, a short-term estrus is observed in the rabbit.

The temperature gradient of the external genital organs of rabbits in estrus is higher than that of animals in diestrus, and thermograms are characterized by large areas of "hot" colors on the palette.

The developed method allows remote (non-contact) to receive the necessary information about the animal's condition, particularly its external genitalia. This makes it possible to objectify and simplify the labor intensity of manipulations to select rabbits for insemination.

Therefore, the research results reliably confirm the regularity of the increase in the temperature of the external genitalia in females of various animal species during the estrus phase, which can be determined remotely (Koshevoj 2013).

4.2. Remote diagnostics of pathological processes in the genital organs of animals

4.2.1 Female

It is known that the ovaries perform a dual function – endocrine and generative. This "biological clock" monitors the state of the animal and its readiness for insemination and fertilization. In this connection, morphological and functional changes are constantly occurring in the mentioned organs. It is known that the ovaries perform a stressful function – even minor influences can change their normal state. Dystrophic and inflammatory processes and functional disorders are the main pathological processes in the ovaries.

It is also known that the endocrine function of the gonads is aimed at producing the main hormones. In particular, the function of estrogens is multifaceted – they, among other things, activate the blood supply to the genitals, including the external ones, which leads to an increase in their temperature.

Determining the functional state of the ovaries and preventive diagnosis of pathological processes in the genitals using thermal imaging can be of priority in animal reproduction. In addition, qualities such as exceptional safety, autonomy, and non-contact make thermal imagers indispensable in veterinary medicine (Stelletta et al 2013; Simões et al 2014; Marquez et al 2021).

4.2.1.1. Gonadopathy

During the thermographic study of cows, the dependence of the temperature gradients of the external genital organs on the morpho-functional state of the ovaries is noted. At the same time, in cows with hypogonadism, the temperature gradient is lower than in animals with normal ovaries. Therefore, with full sexual function, the temperature of the external genital organs is $35.3 \pm 0.1^\circ\text{C}$. In contrast, in animals with hypogonadism, the temperature gradient was lower by 6.4% and 8.1%, respectively, in its II and I stages (Figure 2).

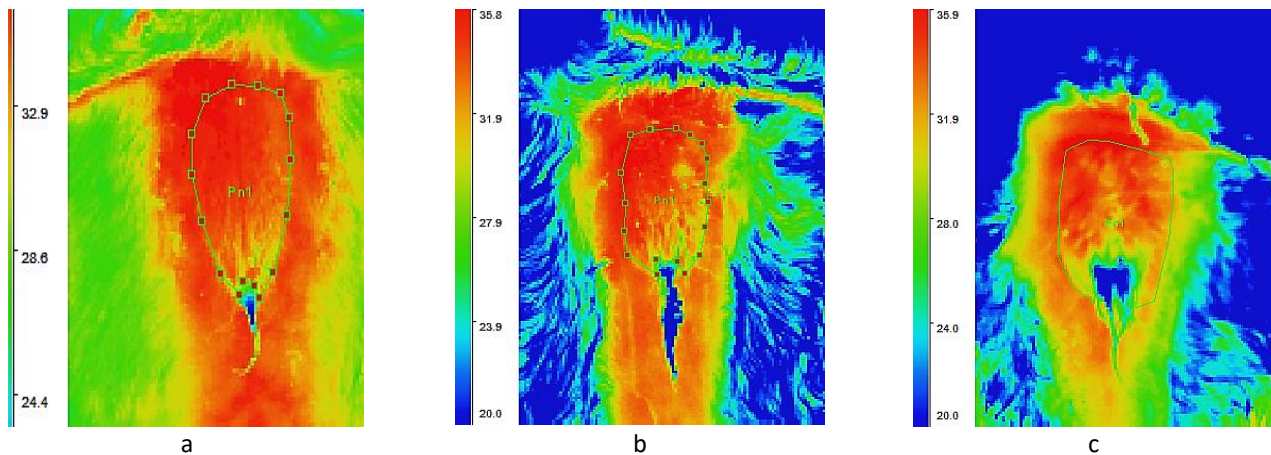


Figure 2 Thermogram of external genital organs of cows: a) with full sexual function; b) with the second stage of hypogonadism; c) with the first stage of hypogonadism. *Source:* Koshevoj (2013).

Differences in thermogram indicators have been established in such cows. In particular, thermograms of the external genital organs of cows with full sexual function are characterized by a predominance of "warm" colors of the palette (red and orange), while in animals with hypogonadism, on the contrary, "cold" colors (blue and green) prevail.

In addition, the thermograms of the genital organs of cows with hypogonadism are characterized by pronounced thermal asymmetry and thermal spotting of the studied area, which are characteristic signs of blood circulation disorders.

The characteristics of thermoscopic and thermographic indicators of the external genital organs of cows with hypoluteolysis are similar to those of hypogonadism. That is, there is a decrease in the temperature gradient and the predominance of "cold" colors in the palette.

During thermoscopic studies of cows with cystic degeneration of ovarian follicles, a sufficiently long increase in the temperature gradient of the external genitalia is noted. Thermograms of the genitals of such animals are characterized by "hot" colors of the palette (Koshevoj 2013).

4.2.1.2. Metro-, vestibulo- et vaginopathy

In inflammatory processes of the reproductive organs, which are registered in animals during the postpartum period and after its end, an increase in local temperature is noted in the external genital organs. Therefore, a method of remote projective thermoscopy is proposed for preventive diagnostics.

Vestibulovaginitis. Typically, the temperature of the external genital organs of cows is $35.3 \pm 0.3^\circ\text{C}$. With vestibulovaginitis, the temperature gradient increases by 3.0%. For thermograms of cows with vestibular vaginitis, "hot" colors of the palette of the organ under study are characteristic.

Metritis. Thermoscopic examination of cows with metritis revealed a difference in the temperature gradient compared to clinically healthy animals. Therefore, if in clinically healthy animals the temperature gradient of the external genitalia was equal to $33.2 \pm 0.5^\circ\text{C}$, then in animals with metritis, it increased to $35.3 \pm 0.3^\circ\text{C}$; that is, it increased by 2.1°C .

The thermogram of the external genitalia of patients with metritis of cows is characterized by the presence of intensely "hot" colors of the palette, which are uniformly registered on the examined organ. The presence of secretions from the external genitalia can also be observed on thermograms. These highlights are usually in "cold" (blue and green shades) palette colors. In a detailed study, inflammatory exudate is differentiated from estrous mucus.

Such research results reliably confirm the regularity of temperature increase during inflammatory processes, which can be determined remotely using thermal imaging technology as a component of preventive diagnostics of pathological processes in the uterus, vagina, and its perineum (Koshevoj 2013; Skliarov et al 2014).

4.2.2. Males

Much literature on thermography is available in diagnosing, monitoring and monitoring and treating andrological pathologies. As a consequence of its use in medical andrology, the interest of andrologists in infrared thermography grew, and

the first studies appeared in the eighties. They showed that thermography could be used to assess thermoregulation of the scrotum/testes, providing an infrared-based image with an accuracy of 0.10 °C. The authors concluded that thermography could be used as an additional screening method in andrological evaluations (Comhaire and Monteyne 1976; Comhaire 1977; Gabor et al 1998; Stelletta et al 2013).

It is known that the testicles perform a double function – sperm and androgenesis. A specific temperature (3-4 °C lower than body temperature) and a sufficient blood supply are required for optimal functioning.

Due to the non-invasiveness and high sensitivity of measuring the temperature difference on the skin surface, it is clear that thermography can be used to monitor the surface temperature of the scrotum (Stelletta et al 2013). With external changes, temperature regulation occurs due to contraction or relaxation of the scrotum. In addition, temperature fluctuations are possible under other circumstances. A decrease in temperature occurs with hemodynamic disorders and dystrophic processes in the gonads, even at the optimal temperature of the external environment. On the contrary, a significant increase in temperature occurs with inflammatory processes (orchitis) and too high a temperature of the external environment (Draaisma 2015; Koshevoj 2017).

Control of the temperature regime in the testicles of males can be carried out remotely using thermal imagers. Express diagnostics are carried out – thermoscopy and thermography, which allow to determine the completeness of the reproductive function and functional state and confirm or exclude pathological processes in the male genital organs (Koshevoj 2013; Naumenko 2017).

4.2.2.1. Testodystrophy, hypogonadism

According to thermoscopic research, the dependence of temperature gradients of testes on their morphofunctional state is noted. At the same time, bulls with dystrophy and hypogonadism have a lower temperature gradient than animals with full reproductive functions. Therefore, the average temperature of the scrotum of animals with full gonadal function is 29.5 ± 0.3 °C, 0.7 °C (0.7%) higher than in bulls with dystrophy and by 1.5 °C – with hypogonadism.

In addition, differences in thermogram indicators have been established in such males. Therefore, the predominance of "warm" colors of the palette (red and orange) is characteristic of the thermograms of spermatozoa of bulls with total reproductive capacity. While thermographic images of testicles of animals with dystrophy and hypogonadism were characterized by pronounced thermospotting of the studied area, the predominance of "cold" colors is typical for blood circulation disorders.

A spotted palette characterized thermographic images of the testicles of wild boars with full reproductive function. In testodystrophy, a slight zone of hypothermia and a decrease in the temperature gradient were observed, while hypogonadism was characterized by pronounced hypothermia and thermal spotting of the studied area.

With the full-fledged sexual function of rams, the thermogram of the testis was characterized by the predominance of "warm" colors and spotting of the pattern; with testodystrophy, a slight zone of hypothermia and a decrease in the temperature gradient was observed, and with hypogonadism, hypothermia, and thermospotting of the studied area with a reduction of the temperature gradient were observed.

Thermographic images of testicles of goats with full-fledged manifestations of reproductive function were characterized by the correspondence of the mosaic and the temperature gradient of the pattern). With testodystrophy and hypogonadism, thermograms were dominated by "cold" palette colors, and thermospotting was observed (Koshevoj 2013; Skliarov et al 2014; Koshevoj et al 2017).

4.2.2.2. Inflammatory processes

Orchitis and balanoposthitis in males are standard, but they are not always diagnosed, making it challenging to register pathologies accurately. For this purpose, preventive remote diagnostics are proposed.

The thermograms of the testes of rabbits with full sexual function were characterized by the correspondence of the mosaic and the temperature gradient. During inflammatory processes, an increase in temperature by 1.3 °C (4.3%), a pronounced zone of hyperthermia, and a predominance of "warm" colors on the palette were observed.

In bulls with balanoposthitis, a temperature increase of 4.6 °C (14.3%), a pronounced zone of hyperthermia with a predominance of "hot" colors of the palette was established (Koshevoj 2013; Koshevoj et al 2017).

Therefore, thermography can be used to assess the functional state of the testicles and preventive diagnosis of andrological diseases.

5. Final considerations

Thermography is a promising non-contact remote diagnostic express method that allows detection differences in the distribution and intensity of infrared radiation depending on the physiological or pathological state of the animal body. In particular, the use of thermal imaging devices reliably confirmed the regularity of the increase in the temperature of the

external genitalia in females of various animal species during the estrus phase, which can be determined remotely by establishing the fertile period.

Therefore, the determination of the functional state of the ovaries and the preventive diagnosis of pathological processes in the genitals with the use of thermal imagers can be of priority importance in the reproduction of animals. Furthermore, exceptional safety, autonomy, and non-contact qualities make thermal imagers indispensable in veterinary medicine.

Therefore, thermography identifies and differentiates the phases of the sexual cycle and preventive diagnosis of obstetric-gynecological and andrological pathologies at a pre- or subclinical stage of development, dystrophic or inflammatory. Practical utilization of thermal imagers enables, in some cases, to make a final diagnostic conclusion; in others, to receive only preventive information followed by thorough, exceptional research.

Ethical Considerations

Not Applicable.

Conflict of Interest

The authors declare no conflict of interest.

Funding

This research did not receive any financial support.

References

- Casas-Alvarado A, Mota-Rojas D, Hernández-Ávalos I, Mora-Medina P, Olmos-Hernández A, Verduzco-Mendoza A., Reyes-Sotelo B, Martínez-Burnes J (2020) Advances in infrared thermography: Surgical aspects, vascular changes, and pain monitoring in veterinary medicine. *Journal of Thermal Biology*. DOI: 10.1016/j.jtherbio.2020.102664
- Comhaire F (1977) Scrotal thermography in patients with varicocele. *Contraception, fertilité, sexualité*. PMID: 12260205
- Comhaire F, Monteyne R (1976) The value of scrotal thermography as compared with selective retrograde venography of the internal spermatic vein for the diagnosis of "subclinical" varicocele. *Fertility and Sterility*. DOI: 10.1016/S0015-0282(16)41901-1
- De Freitas ACB, Vega WHO, Quirino CR, Junior AB, David CMG, Geraldo AT, Rua MAS, Rojas LFC, Filho JEA, Dias AJB (2018). Surface temperature of ewes during estrous cycle measured by infrared thermography. *Theriogenology*. DOI: 10.1016/j.theriogenology.2018.07.015
- Draaisma HS (2015) Application of infrared scrotal thermography (IRST) under field conditions in bulls extensively managed in tropical Costa Rica, and its relationship with spermogramme, clinical variables and final breeding soundness classification [Electronic resource]. Available in: <https://studenttheses.uu.nl/handle/20.500.12932/20344> Accessed on: May 21, 2022.
- Gabor G, Sasser RG, Kastelic JP, Coulter GH, Falkay G, Mézes M, Bozò S, Volgyi-Csik J, Barany I, Szasz F Jr (1998) Morphologic, endocrine and thermographic measurements of testicles in comparison with semen characteristics in mature Holstein-Friesian breeding bulls. *Animal reproduction science*. DOI: 10.1016/S0378-4320(98)00077-3
- Gade R, Moeslund TB (2014) Thermal cameras and applications: a survey. *Machine vision and applications*. DOI: 10.1007/s00138-013-0570-5
- Hurnik JF, Webster AB, De Boer S (1985) An investigation of skin temperature differentials in relation to estrus in dairy cattle using a thermal infrared scanning technique. *Journal of Animal Science*. DOI: 10.2527/jas1985.6151095x
- Jeyakumar S, Kumaresan A, Katakataware MA, Manimaran A, Ramesha KP (2022) Infrared Thermal Imaging and Its Application in Animal Reproduction. In: *Frontier Technologies in Bovine Reproduction*. Springer Nature Singapore, Singapore, pp 47-64.
- Knizkova I, Kunc P, Gürdil G, Pinar Y, Selvi KÇ (2007) Applications of infrared thermography in animal production. *Anadolu Tarım Bilimleri Dergisi* 22(3):329-336.
- Koshevoj VP (ed) (2013) *Termografichna diagnostyka u veterynarnomu akusherstvi, ginekologii' ta andrologii'* [Thermographic diagnostics in veterinary obstetrics, gynecology and andrology]. RVV HDZVA, Harkiv.
- Koshevoj VP (ed) (2015) *Imunobiologija laktacii' u tvaryn* [Immunobiology of lactation in animals]. Gerda, Dnipropetrovs'k.
- Koshevoj VP, Naumenko SV, Koshevoj VI, Skliarov PM (2017) *Dystancijno-bezkontaktna ta neinvazijna diagnostyka patologichnyh procesiv u gonadah samciv* [Remote non-contact and non-invasive diagnosis of pathological processes in male gonads]. RVV HDZVA, Harkiv.
- Kunc P, Knizkova I (2012) The use of infrared thermography in livestock production and veterinary field. In: *Infrared Thermography Recent Advances and Future Trends*. Bentham Books, Sharjah, United Arab Emirates, pp 85-101.
- Marquez HP, Ambrose DJ, Schaefer AL, Cook NJ, Bench CJ (2021) Evaluation of infrared thermography combined with behavioral biometrics for estrus detection in naturally cycling dairy cows. *Animal*. DOI: 10.1016/j.animal.2021.100205
- McManus C, Tanure CB, Peripolli V, Seixas L, Fischer V, Gabbi AM, Menegassi SRO, Stumpf MT, Kolling GJ, Dias E, Costa Jr JBG (2016) Infrared thermography in animal production: An overview. *Computers and Electronics in Agriculture*. DOI: 10.1016/j.compag.2016.01.027
- Mota-Rojas D, Martínez-Burnes J, Casas-Alvarado A, Gómez-Prado J, Hernández-Ávalos I, Domínguez-Oliva A, Lezama-García K, Jacome-Romero J, Rodríguez-González D, Pereira, MF (2022). Clinical usefulness of infrared thermography to detect sick animals: Frequent and current cases. *CABI Reviews*. DOI: 10.1079/cabreviews20221704
- Nääs IA, Garcia RG, Caldara FR (2020) Infrared thermal image for assessing animal health and welfare. *Journal of Animal Behaviour and Biometeorology*. DOI: 10.14269/2318-1265/jabb.v2n3p66-72
- Naumenko SV (2017) Distance non-contact and non-invasive diagnostics pathological processes in gonads male small animals. *Science and Technology Bulletin of SRC for Biosafety and Environmental Control of AIC* 5(1):13-18.

- Pamungkas FA, Purwanto BP, Manalu W, Sianturi RG (2022) Application of infrared thermography as a determinant of estrous conditions of Sapera dairy goats. *Agriculture and Natural Resources* 56(6):1207-1214.
- Pasternak AM, Skliarov PM, Zhygalova OJe (2017) Termografichna diagnostyka mastytiv i i'i kontrol' na mikrostrukturnomu rivni [Thermographic diagnosis of mastitis and its control at the microstructural level]. *Scientific Messenger of Lviv National University of Veterinary Medicine and Biotechnologies*. DOI: 10.15421/nvlvet8233
- Rekant SI, Lyons MA, Pacheco JM, Arzt J, Rodriguez LL (2016) Veterinary applications of infrared thermography. *American journal of veterinary research*. DOI: 10.2460/ajvr.77.1.98
- Roberto JVB, De Souza BB (2020) Use of infrared thermography in veterinary medicine and animal production. *Journal of Animal Behaviour and Biometeorology*. DOI: 10.14269/2318-1265/jabb.v2n3p73-84
- Simões VG, Lyazrhi F, Picard-Hagen N, Gayrard V, Martineau GP, Waret-Szkuta A (2014) Variations in the vulvar temperature of sows during proestrus and estrus as determined by infrared thermography and its relation to ovulation. *Theriogenology*. DOI: 10.1016/j.theriogenology.2014.07.017
- Skliarov P, Fedorenko S, Naumenko S, Bilyi D, Onyshchenko O (2022) Innovations of veterinary reproductology in collaboration with related science. In: *Innovations in modern medicine and biology: collective monograph*. Primedia eLaunch, Boston, pp 104-127.
- Skliarov P, Pérez-Marín CC, Petrusa VH, Onyshchenko OV, Fedorenko SY, Kibkalo DV (2022) Determining the optimal time of insemination of goats using a thermal imager. *Theoretical and Applied Veterinary Medicine*. DOI: 10.32819/2022.10006
- Skliarov PM, Fedorenko SJa, Naumenko SV, Ivanchenko MM, Onyshchenko OV, Pasternak AM, Koshevoj VI (2019) Innovacijni rozrobky shkoly veterynarnyh reproductologiv profesora V.P. Koshevogo [Innovative developments of the school of veterinary reproductive specialists of professor V.P. Koshevoj]. *RVV HDZVA, Harkiv*.
- Skliarov PM, Koshevoj VP, Fedorenko SJa (2014) Vykorystannja termografii' v reprodukcii' ovec' ta kiz [The use of thermography in the reproduction of sheep and goats]. *Visnyk Zhytomyrs'kogo nacional'nogo agroekologichnogo universytetu* 2(46):116-121.
- Stachurska A, Kędzierski W, Kaczmarek B, Wiśniewska A, Żylińska B, Janczarek I (2023) Variation of physiological and behavioural parameters during the oestrous cycle in mares. *Animals*. DOI: 10.3390/ani13020211
- Stelletta C, Vencato J, Fiore E, Giancesella M (2013) Infrared thermography in reproduction. *Thermography current status and advances in livestock animals and in veterinary medicine*. Brescia, Rome, pp 113-125.
- Sykes DJ, Couvillion JS, Cromiak A, Bowers S, Schenck E, Crenshaw M, Ryan PL (2012) The use of digital infrared thermal imaging to detect estrus in gilts. *Theriogenology*. DOI: 10.1016/j.theriogenology.2012.01.030
- Tattersall GJ (2016) Infrared thermography: A non-invasive window into thermal physiology. *Comparative Biochemistry and Physiology Part A: Molecular & Integrative Physiology*. DOI: 10.1016/j.cbpa.2016.02.022
- Vicentini RR, Montanholi YR, Veroneze R, Oliveira AP, Lima ML, Ujita A, El Faro L (2020) Infrared thermography reveals surface body temperature changes during proestrus and estrus reproductive phases in Gyr heifers (*Bos taurus indicus*). *Journal of Thermal Biology*. DOI: 10.1016/j.jtherbio.2020.102662